

© КОЛЛЕКТИВ АВТОРОВ, 2021

UDC 616.216-002-07

A. Cheșcă^{1*}, G. A. Gyurka¹

SINUSITIS: BASIC IMAGING ASPECTS

Faculty of Medicine, Transilvania University of Brașov (Brașov, Romania)

*Antonella Cheșcă – Head of Imagistics Lab. at Lung Phthysiology Hospital (Brașov, Romania);

e-mail: anto.chesca@gmail.com

This study aims to present the theoretical data on sinusitis, as an adjacent pathology of the upper respiratory tract infections. In addition, it will present radiological images representing diagnostic methods used in the pathology of sinuses. From this point of view, natively made computer tomographic images will be presented, having as reference the conventional radiography of sinuses. There were made images of two female patients who came to the specialized ambulatory having signs and symptoms of acute sinus infections.

Key words: sinusitis, cases, diagnostic, imaging aspects

Nowadays, the incidence of respiratory infections is at high level. This fact is caused by numerous risk factors and determining factors predisposing and contributing to the appearance of signs and symptoms of these types of pathologies [2].

In the context of respiratory pathology, there are some cases in which respiratory pathology can be associated with sinus infections [16]. From this point of view we can recall that upper respiratory tract infections often can be the consequence of sinus infections which had not been treated correctly and on time [8, 13]. Sinus pathology is common in any age group, considering the existence of numerous factors which contribute to the occurrence of this pathology [7, 15]. Clinically, sinusitis can be classified into acute and chronic [10, 12]. Acute sinusitis is caused by incorrectly or insufficiently treated viral or bacterial infections. The most common signs of the occurrence of this pathology are stuffy nose, accompanied by runny nose, cough, fever, headache, pain in the ears [5, 6].

Chronic sinusitis occurs as a result of incorrectly or insufficiently treated repeated bacterial infections. Frequently, however, it can be caused by a chronic inflammatory disease that affects the upper respiratory tract and that may show symptoms specific to asthma, considering the influence of respiratory allergies as predisposing factor. In this context, decreased immunity and the low defense ability against infections are major risk factors in chronic sinus infections. Chronic sinusitis is characterized by a variety and complexity of forms, therefore it is imperative a specialized medical consult in order to establish an appropriate diagnosis and treatment [3, 8].

The methods of diagnosis of sinusitis are the performing conventional radiography of the

sinuses and native CT scanning [1, 14]. These methods are joined by those used by Otorhinolaryngology physicians who perform, when required, endoscopic examinations by using optical fibre instruments [4, 11]. This method allows, by exploring areas in detail, to observe barely visible structural aspects of high accuracy that can be used as diagnostic support [9, 17].

Antibiotic treatment associated with anti-inflammatory and other types of drugs are required in sinusitis. In this type of pathology the treatment must be individualized and specific to each patient, according to the form of the disease. In the context of the incidence of the pathology extensively presented previously, this study aims to present diagnostic aspects of sinusitis.

MATERIALS AND METHODS

Radiological images were analyzed for this study. Conventional radiography is usually used as a routine investigation to examine the sinuses. As specific investigation, native computed tomography is preferred according to the recommendations of specialized physicians. In the following we will present particular issues concerning imagistic changes in sinusitis, using both standard radiography and computed tomography images. To carry out this study radiological aspects of two female patients, aged 41-50, were selected.

RESULTS AND DISCUSSION

The study presents the cases of two female patients who came to the specialized ambulatory accusing symptoms of sinusitis. In order to establish a diagnosis, in addition to clinical examination, imaging investigations were made using conventional imaging and native computer tomography. The standard radiographic image shown in this study highlights the skull bone and the aspect of the frontal, maxillary and paranasal

sinuses. In this context, the image presented in this paper reveals changes in the frontal and a buckling of the maxillary sinus, accompanied by thickening of the ethmoid's lining. (fig. 1).

Computed tomography images show dense, inclined fluid accumulation at right maxillary sinus level associated with circumferential mucosal thickening and polypoid mucosal thickening of the lining of the paranasal sinuses and of the right inferior and middle cornets. These issues are revealed on computed tomography reconstructions performed in axial plane. (fig. 2, 3). Also, axial computed tomography reconstructions show dense fluid accumulation at anterior and

posterior ethmoid cells level and at right sphenoid sinus level as well (fig. 2, 3).

The changes in sinusitis shown above can be seen on computed tomography image reconstructions of images obtained in coronal plane modus. (fig. 4, 5).

Native examination computed tomography images emphasize circumferential thickening of the frontal sinus mucosa, without evidencing the heterodense infra and supratentorial intracerebral lesions. These structures can be observed in axial, as well as coronal reconstructions in the figures above. The reconstructed coronal computed

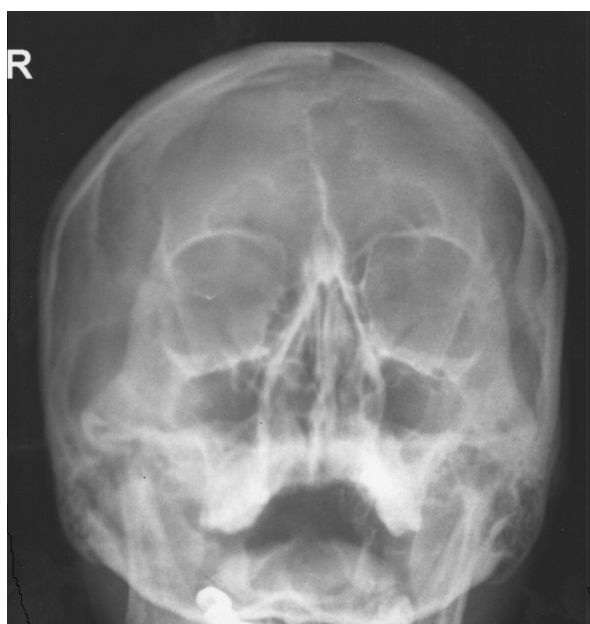

Figure 1 – Standard X-ray image

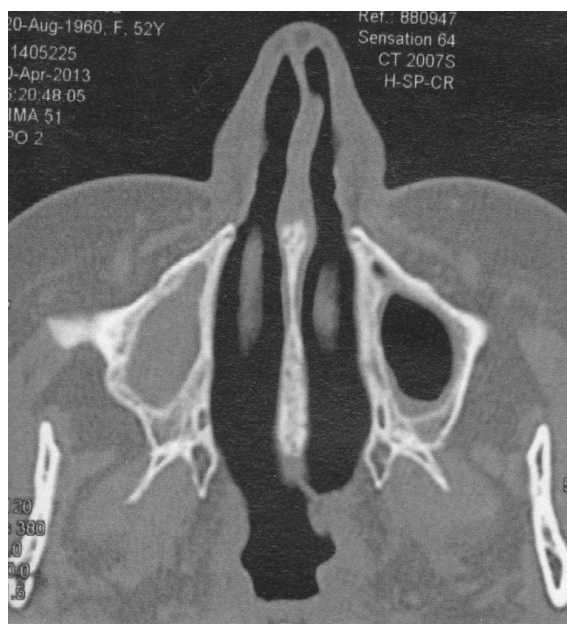

Figure 2 – CT image. Native examination

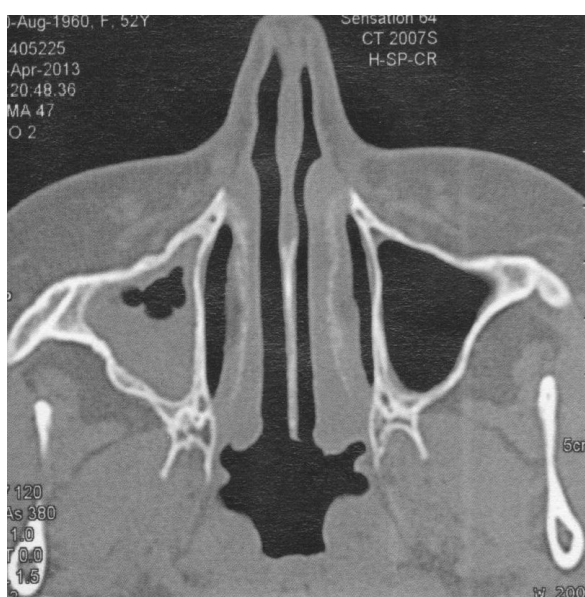

Figure 3 – CT image. Native examination

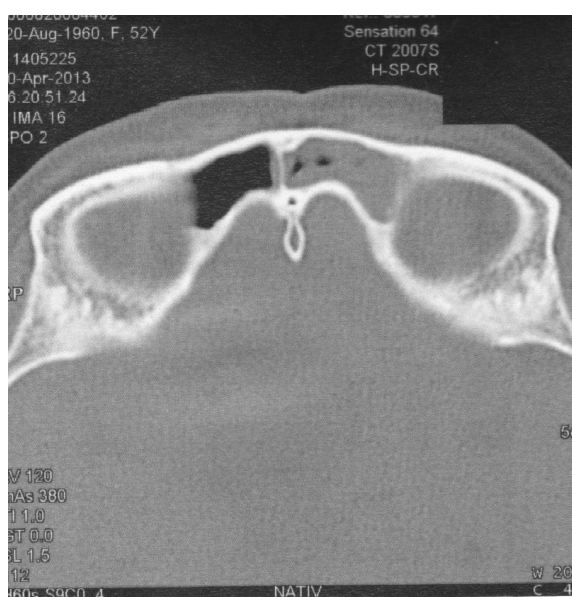

Figure 4 – CT image. Native examination

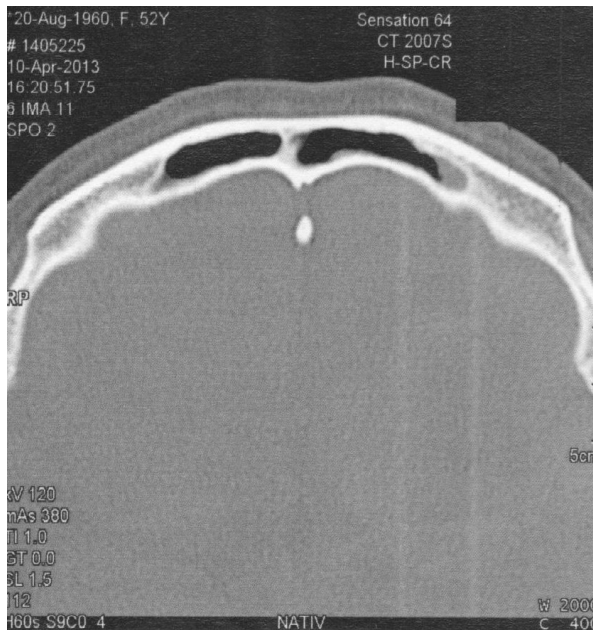

Figure 5 – CT image. Native examination

tomography images highlight the aspect of the frontal sinus (fig. 6).

Coronal computed tomography reconstructed images can also highlight the morphology of the maxillar sinuses (fig. 7).

By observing the imagistic changes, the female patient from whom the computed tomography images were selected, was diagnosed with

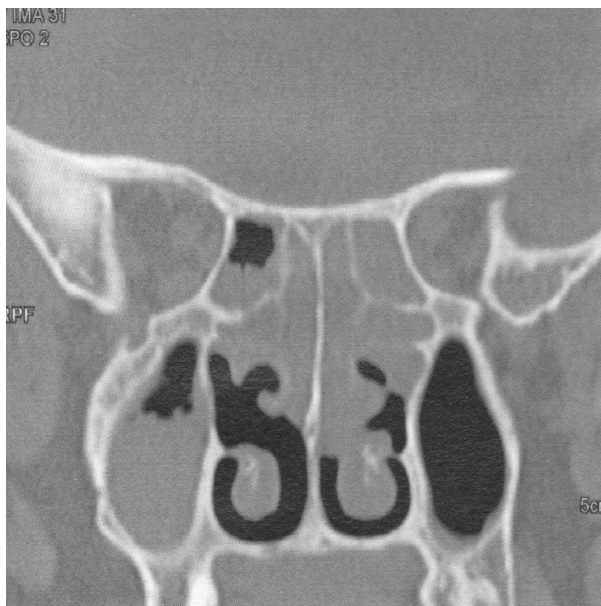


Figure 7 – CT image. Native examination

chronic sphenoid and facial parasinusitis without detectable brain lesions. In the case of the first female patient, the diagnosis of chronic maxillary and frontal sinusitis was established, observing the changes and analyzing the data obtained by conventional radiography.

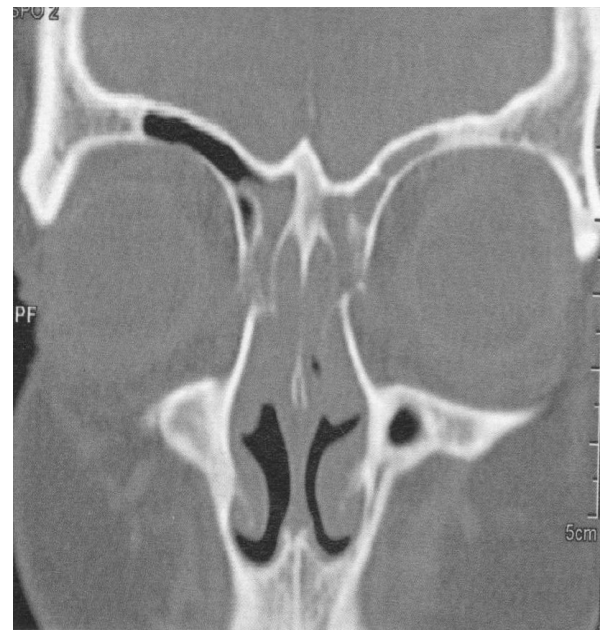


Figure 6 – CT image. Native examination

Given the high incidence of sinusitis in different age groups, in both sexes, and due to the issues presented in this case study, greater attention should be paid to this pathology. From this point of view, preventively, it is worth presenting information materials regarding this pathology and the consequences of incorrect diagnosis and improperly administered medications in public institutions.

REFERENCES

- 1 Benson M. L. Nasal and paranasal sinus imaging /M. L. Benson, P. J. Oliverio, S. J. Zinreich //Journal belge de radiologie. – 1997. – V. 80(2). – P. 89-91.
- 2 Bolger W. E. Changing concepts in chronic sinusitis /W. E. Bolger, D. W. Kennedy // Hospital practice. – 1992. – V. 27(9). – P. 20-28.
- 3 Druce H. M. Emerging techniques in the diagnosis of sinusitis //Annals of allergy. – 1991. – V. 66(2). – P. 132-136.
- 4 Ferrié J. C. Paranasal sinuses and facial imaging: exploratory strategies /J. C. Ferrié, J. M. Klossek //Journal de radiologie. – 2003. – V. 84. – P. 963-967.
- 5 Friedman W. H. Diagnosis and medical and surgical treatment of sinusitis in adults /W. H. Friedman, R. G. Slavin //Clinical reviews in allergy. – 1984. – V. 2(4). – P. 409-428.
- 6 Hildmann H. Sinusitis in the child from the ENT specialty point of view //Fortschritte der Medizin. – 1991. – V. 109(19). – P. 397-400.
- 7 Ide C. Chronic sinusitis: the role of imaging /C. Ide, J. P. Trigaux, P. Eloy //Acta oto-rhino-laryngologica. – 1997. – V. 51(4). – P. 247-258.
- 8 Jorissen M. Recent trends in the diagno-

sis and treatment of sinusitis. //European radiology. – 1996. – V. 6(2). – P. 170-176.

9 Lazar R. H. The current management of sinusitis in children /R. H. Lazar, R. T. Younis // Clinical pediatrics. – 1992. – V. 31(1). – P. 30-36.

10 Lund V. J. Staging for rhinosinusitis /V. J. Lund, D. W. Kennedy //Otolaryngology – head and neck surgery. – 1997. – V. 117. – P. 35-40.

11 Mafee M. F. Modern imaging of paranasal sinuses and the role of limited sinus computerized tomography; considerations of time, cost and radiation //Ear, nose, & throat journal. – 1994. – V. 73(8). – P. 532-534.

12 Moulin G. Radiologic imaging of chronic sinusitis in the adult /G. Moulin, T. Pascal, A. Jacquier //Journal de radiologie. – 2003. – V. 84. – P. 901-919.

13 Ott N. L. Childhood sinusitis /N. L. Ott, E. J. O'Connell, A. D. Hoffmans //Mayo Clinic proceedings. – 1991. – V. 66(12). – P. 1238-1247.

14 Roithmann R. CT-imaging in the diagnosis and treatment of sinus disease: a partnership between the radiologist and the otolaryngologist / R. Roithmann, L Shankar, M. Hawke //The Journal of otolaryngology. – 1993. – V. 22(4). – P. 253-260.

15 Willner A. Sinusitis in children: current management /A. Willner, R. H. Lazar, R. T. Younis //Ear, nose, & throat journal. – 1994. – V. 73(7). – P. 485-491.

16 Zeifer B. Update on sinonasal imaging: anatomy and inflammatory disease // Neuroimaging clinics of North America. – 1998. – V. 8(3). – P. 607-630.

17 Zinreich S. J. Imaging of chronic sinusitis in adults: X-ray, computed tomography, and magnetic resonance imaging //The Journal of allergy and clinical immunology. – 1992. – V. 90. – P. 445-451.

Received 04.07.2021

А. Ческа¹, Г. А. Гюрка¹

СИНУСИТЫ: БАЗОВЫЕ ВОЗМОЖНОСТИ ВИЗУАЛЬНОЙ ДИАГНОСТИКИ

¹Медицинский факультет Трансильванского университета г. Брашов (Брашов, Румыния)

*Антонелла Ческа – руководитель лаборатории визуальных методов, Больница фтизиатрии легких (Брашов, Румыния); электронная почта: anto.chesca@gmail.com

Проведенное исследование имело цель представить теоретические данные о синуситах как сопутствующей патологии при инфекциях верхних дыхательных путей. В статье представлены радиологические изображения, демонстрирующие возможности диагностических методов, используемых при патологии носовых пазух. С этой точки зрения, будут представлены как изображения, сделанные при компьютерной томографии, так и при использовании метода традиционной рентгенографии придаточных пазух носа. В статье представлены снимки носовых пазух двух пациентов женского пола, которые обратились за специализированной амбулаторной помощью с признаками и симптомами острого инфекционного синусита.

Ключевые слова: синусит, клинический случай, диагностика, визуальные методы

А. Ческа^{1}, Г. А. Гюрка¹*

СИНУСИТ: БЕЙНЕЛЕУДИҢ НЕГІЗГІ АСПЕКТІЛЕРІ

Брашов Трансильвания университетінің медицина факультеті (Брашов, Румыния)

*Антонелла Ческа – Imagistics зертханасының меңгерушісі. Өкпенің фтизиатриялық ауруханасында (Брашов, Румыния); электрондық поштасы: anto.chesca@gmail.com

Жүргізілген зерттеудің мақсаты жоғары тыныс алу жолдарының инфекциясы кезінде қосалқы патология ретінде синуситтар туралы теориялық мәліметтер алуды мақсат етті. Мақалада мұрын қуысы патологиясы кезінде қолданылатын диагностикалық әдістердің мүмкіндіктерін көрсететін радиологиялық көріністер ұсынылған. Осы көзқарас тұрғысынан компьютерлік томография кезінде жасалған және мұрын қуысын дәстүрлі рентгенографиялау әдісін қолдану кезінде жасалған көріністер ұсынылады. Мақалада өткір инфекциялық синусит белгілерімен және симптомдарымен арнайы амбулаториялық көмекке жүгінген екі әйел пациенттің мұрын қуысының суреттері ұсынылған.

Кілт сөздер: синусит, клиникалық жағдай, диагностика, визуалдық әдістер