

D. K. Yesniyazov, N. T. Abatov, M.M. Tussupbekova, R. M. Badyrov, Ye. M. Assamidanov

## DECELLULARIZED MATRIX OF XENOPERITONEUM: A QUANTITATIVE ASSESSMENT OF HEARING SENSE PRESENCE AFTER MYRINGOPLASTY WITH A BIOLOGICAL IMPLANT IN AN EXPERIMENT

Karaganda medical university (Karaganda, Kazakhstan)

The authors proposed a new biological material for the tympanic membrane plastic surgery – the decellularized matrix of xenoperitoneum. The objective of the work was the quantitative assessment of hearing sense presence after myringoplasty using decellularized xenoperitoneal matrix in an experiment. A comparative characteristic of hearing sense was performed after myringoplasty with decellularized xenoperitoneal matrix and canned cadaver pachymeninx using the method of brainstem auditory evoked response (BAER-test), based on the assessment of the total length of three more expressed peaks in the audiogram. There were no statistically significant differences between a healthy ear and an operated ear with a new biological implant according to the results of the average values of the sum of the three peaks in the audiogram ( $53.2 \pm 13.55$  mm and  $40.6 \pm 9.77$  mm, respectively ( $p > 0.05$ )). Hearing acuity after myringoplasty with decellularized matrix of xenoperitoneum was significantly restored to original values.

*Key words:* BAER-test, decellularized matrix of xenoperitoneum, biological implant, myringoplasty, tympanic membrane perforation

The problem of hearing impairment in modern society is becoming increasingly relevant; the hearing impairment equally affects the quality of life and the communicative capabilities of any person regardless of the severity [1]. According to the World Health Organization (WHO), 360 million people (including 32 million children) worldwide suffer from disabling hearing loss (hearing loss in a better hearing ear, exceeding 40 dB in adults and 30 dB in children). The hearing impairment is registered in 14% people at the age from 45 to 64 years and in 30% over 65 years.

The causes of hearing loss can be divided into two main groups: congenital and acquired. Congenital hearing loss can be caused by hereditary and non-hereditary genetic factors or complications during pregnancy. Acquired hearing loss develops at any age, and in most cases lends itself well to treatment [9]. The hearing loss is divided as conductive and sensorineural according to the pathogenesis of the development. Currently, many methods have been proposed for auditory function deficiency correcting; we performed operations to correct conductive hearing loss in our work.

The various plastic materials are used in clinical practice: temporal muscle fascia, cartilage and perichondrium, periosteum, mucous membrane of the cheek, mucous membrane of the small intestine, nasal septum, vein wall, dura mater, amnion, sclera, human allofibroblast culture, polymer implants, two and three-layer grafts of different composition [3, 4, 7, 8, 10]. But these grafts along with sufficient efficiency have significant drawbacks identified during many years of

clinical trials. Possible complications include supuration, flap dislocation or graft rejection; collagen fibers dissolve at scarring and often do not completely cover the tympanic membrane defect, recurrence of the tympanic membrane defect, adhesion to the medial wall of the tympanic cavity, which significantly reduces the function of the tympanic membrane and as a result of hearing loss. The search and development of new highly effective materials to restore the integrity of the eardrum is still ongoing. A new biological material is presented in our work – decellularized matrix of xenoperitoneum in an experiment on rabbits.

In presence, the most objective and widespread method of hearing testing in animals is the method of brainstem auditory evoked response (BAER-test). An assessment of hearing in animals using this method has been carried out for a long time. We met a quantitative assessment of hearing in animals in the works of I. V. Chuvayev (the Clinic of LLC «Institute of Veterinary Biology»), which was of considerable interest to us from the point of view of quantifying hearing acuity in experimental animals [2].

The **objective** was the quantitative assessment of hearing sense presence after myringoplasty using decellularized matrix of xenoperitoneum in an experiment.

### MATERIALS AND METHODS

The object of a comparative experimental study is a new biological implant of domestic development - decellularized bovine-derived peritoneum matrix used for tympanic membrane repair for the first time. The decellularized matrix of xenoperitoneum was obtained by a double cycle of decellularization with the detergent-enzymatic

method followed by sterilization with gamma-radiation [5]. The canned cadaver dura mater (pachymeninx), a biological material used in clinical practice for plastic surgery of the tympanic membrane during perforations, was used as the comparison material.

The experiment was conducted on 20 sexually mature rabbits of both sexes, weighing  $2000 \pm 500$  grams. Animals were distributed in two groups, randomly. The groups corresponded to the used bioimplant: group I – the decellularized matrix of xenoperitoneum, group II – canned dura mater. The tympanic membrane defect and subsequent myringoplasty [2] were fulfilled in all animals on the left ears, the right ears were the control.

A quantitative assessment of hearing was performed on the 30<sup>th</sup> day after the surgery using the BAERCOM UFI recorder of brainstem auditory evoked response, a standard simulator of the brain neuro-wave activity, and standard BAERCOM PC software. The power of the sound pulse packet is 70 dB.

A three-electrode system of subcutaneous electrodes was used when registering an audiogram: two active electrodes (right, left ear) and a third reference electrode (in the parietal tubercle area). Poly-frequency impulses were sent by 25 packets and displayed for the right and left ear separately (fig. 1). The test was performed three times in each ear to avoid spontaneous errors.

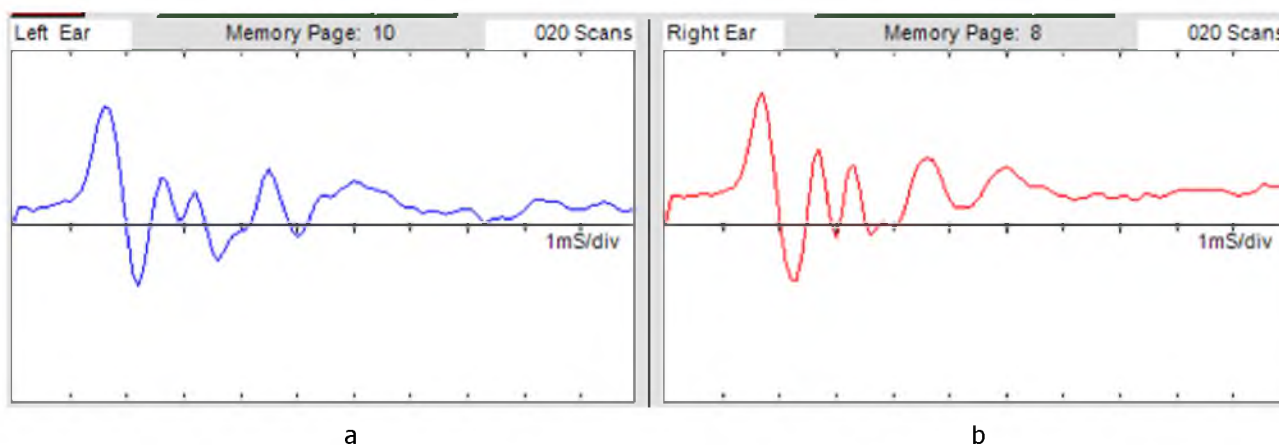


Figure 1 – Audiogram obtained using simulator of neuro-wave activity on the 30<sup>th</sup> day after myringoplasty with decellularized matrix of xenoperitoneum: a) left ear, b) right ear

A comparative analysis of hearing acuity was performed between the first and second groups in accordance with the used bioimplant, as well as the operated ear with a healthy one.

**Statistical analysis.** The group arithmetic mean ( $\bar{X}$ ) and standard deviation (SD) were calculated for all quantitative data. The significance of differences between the study groups was determined using the non-parametric Mann – Whitney criterion to compare the independent groups («experience – control»). The changes were considered statistically significant at a confidence level  $p < 0.05$ .

Experimental work with animals was carried out in accordance with the European Convention for the Protection of Vertebrate Animals Used for Experimental Purposes (Helsinki Declaration of the World Medical Organization). The experimental study was approved by the Committee on Bioethics of Non-profit joint-stock company «Karaganda Medical University», protocol №12 from 02.06.19.

## RESEARCH RESULTS

It was necessary to formalize the graphs to quantify the results and at the same time to obtain a digital value that reflects as much as possible the generalized result of each individual study. To this end, we measured the height of the three most expressed peaks after setting the standard contour and bringing all the graphs in line with it. Peak height (in mm) was measured for each study separately. Then the height of three peaks was summarized and total numerical value expressed in mm was obtained [6]. The results of the study are presented in table 1.

The table presents, that the total value of the audiograms peaks of unoperated right ear was higher than the data of the operated left ear in both groups. However, there were no statistically significant differences between the average values of three peaks sum in the audiogram of the operated and non-operated ears in the first group, where the decellularized matrix of xenoperitoneum was applied –  $40.6 \pm 9.77$  mm and

Table 1 – Comparative assessment of the audiogram data on the 30<sup>th</sup> day after myringoplasty

Measurement result (mm)	Decellularized matrix of xenoperitoneum, ( $\bar{x}$ )	Canned cadaver pachymeninx, ( $\bar{x}$ )
Sum of three peaks (mm) – left ear	40,6±9,77	32,2±3,36
Sum of three peaks (mm) – right ear	53,2±13,55	43,8±0,84
Total sum (mm) – left and right ears	96,2±11,78	74,6±3,21
p-value	p=0,096	p=0,001

53.2±13.55 mm, respectively ( $p>0.05$ ). This phenomenon can be regarded as the auditory functions restoration of the middle ear after myringoplasty.

The average values of three peaks sum of the in the audiogram of the operated (left) ear were statistically significantly different from the values of the unoperated (right) ear in the second group, where canned dura mater (pachymeninx) was used for the eardrum – 32.2 ±3.36 mm versus 43.8±0,84 mm ( $p<0.05$ ), which may indicate a lower ability of this type of biological implant to restore auditory functions of the middle ear after myringoplasty.

Comparative analysis of the total peaks value of the right and left ears in two groups revealed that the total peaks value of the right and left ears (96.2±11.78 mm) when using the decellularized matrix of xenoperitoneum was statistically significantly larger ( $p<0.05$ ) than in the comparison group – 74.6 ± 3.21 mm.

### CONCLUSIONS

Thus, the obtained results demonstrate that hearing acuity after myringoplasty with new biological material decellularized matrix of xenoperitoneum was higher (closer to the initial values) than with canned dura mater.

### REFERENCES

1 Chuvaev I. V. Quantification of hearing acuity in animals during the BAER test //Actual issues of veterinary biology. – 2016. – V. 3 (31). – S. 213-216.

2 Chuvaev I. V. The influence of various factors on conducting a BAER test in dogs, errors and artifacts //Actual issues of veterinary biology. – 2017. – V. 1 (33). – S. 123-126.

3 Haisch A. Functional and audiological results of tympanoplasty type I using pure perichondrial grafts //HNO. – 2013. – V. 61. – P. 602-608.

4 Hakimov A. M. Miringoplastika s primeneniem ksenotransplantata iz perikarda ovcy /A. M. Hakimov, R. I. Isroilov, A. Zh. Botirov // Rossijskaja otorinolaringologija. – 2011. – №6 (55). – S. 169-173.

5 Izuchenie biomehanicheskikh svojstv novogo biologicheskogo implantata na osnove vnekletchnogo matriksa ksenobryushiny dlja plastiki defektov perednej brjushnoj stenki /R. M. Badyrov, N. T. Abatov, M. M. Tusupbekova et al. // Medicina i jekologija. – 2018. – V. 1. – S. 123-127.

6 Metod miringoplastiki s primeneniem decelljuljarizirovannogo matriksa ksenobryushiny v jeksperimente /D. K. Esnijazov, N. T. Abatov, R. M. Badyrov et al. //Materialy mezhdunarodnoj nauchno-prakticheskoy konferencii (67-oj godichnoj), posvjashhennoj 80-letiju TGMU im. Abuali ibni Sino. – 2019. – T.1. – S. 213-215.

7 Onal K. Perichondrium cartilage island flap and temporalis muscle fascia in type I tympanoplasty //J. Otolaryngol. Head Neck Surg. – 2011. – V. 40 (4). – P. 295-299.

8 Peng R. Efficacy of «hammock» tympanoplasty in the treatment of anterior perforations /R. Peng, A. K. Lalwani //Laryngoscope. – 2013. – V. 123. – P. 1236-1240.

9 Priobretennaja patologija vnutrennego uha kak faktor, oslozhnjajushhij hirurgicheskij jetap kohlearnoj implantacii /V. E. Kuzovkov, A. S. Lilenko, S. B. Sugarova, I. V. Kostevich //Consilium Medicum. – 2018. – V. 20 (3). – P. 80-84.

10 Razan A. Basonbul, Michael S. Cohen. Use of porcine small intestinal submucosa for pediatric endoscopic tympanic membrane repair // World Journal of Otorhinolaryngology – Head and Neck Surgery. – 2017. – V. 3. – S. 142-147.

Поступила 02.05.2020 г.

*Д. К. Есниязов, Н. Т. Абатов, М. М. Тусупбекова, Р. М. Бадыров, Е. М. Асамиданов*  
**ДЕЦЕЛЛЮЛЯРИЗОВАННЫЙ МАТРИКС КСЕНОБРЮШИНЫ: КОЛИЧЕСТВЕННАЯ ОЦЕНКА НАЛИЧИЯ СЛУХА ПОСЛЕ МИРИНГОПЛАСТИКИ БИОЛОГИЧЕСКИМ ИМПЛАНТАТОМ В ЭКСПЕРИМЕНТЕ**  
*Медицинский университет Караганды (Караганда, Казахстан)*

Предложен новый биологический материал для пластики барабанной перепонки – децеллюляризованный матрикс ксенобрюшины. Цель работы – дать количественную оценку наличия слуха после мирингопластики с применением децеллюляризованного матрикса ксенобрюшины в эксперименте. С помощью метода вызванных слуховых потенциалов (BAER-тест), основанного на оценке суммарной длины трех более выраженных пиков на аудиограмме, дана сравнительная характеристика слуха после мирингопластики децеллюляризованным матриксом ксенобрюшины и консервированной твердой мозговой оболочкой кадавра.

По результатам средних значений суммы трех пиков аудиограммы статистически значимых различий между здоровым ухом и оперированным ухом с новым биологическим имплантатом не выявлено –  $53,2 \pm 13,55$  мм и  $40,6 \pm 9,77$  мм соответственно ( $p > 0,05$ ). Острота слуха после мирингопластики с применением децеллюляризованного матрикса ксенобрюшины значимо восстанавливается к исходным значениям.

*Ключевые слова:* BAER тест, децеллюляризованный матрикс ксенобрюшины, биологический имплантат, мирингопластика, перфорация барабанной перепонки

*Д. К. Есниязов, Н. Т. Абатов, М. М. Тусупбекова, Р. М. Бадыров, Е. М. Асамиданов*  
**ДЕЦЕЛЛЮЛЯРИЗАЦИЯЛАНҒАН КСЕНОҚҰРСАҚ МАТРИКСІН: ЭКСПЕРИМЕНТТЕ БИОЛОГИЯЛЫҚ ИМПЛАНТПЕН МИРИНГОПЛАСТИКАЛАУДАН КЕЙІНГІ ЕСТҮ ҚАБІЛЕТІН САНДЫҚ БАҒАЛАУ**  
*Қарағанды медицина университеті (Қарағанды, Қазақстан)*

Дабыл жарғағының пластикасына арналған децеллюляризацияланған ксеноқұрсақ матриксінің жаңа биологиялық материалы ұсынылды. Жұмыстың мақсаты - экспериментте децеллюляризацияланған ксеноқұрсақ матриксін пайдалана отырып, биологиялық имплантпен мирингопластикалаудан кейінгі есту қабілетін сандық бағалау. Аудиограммада айқындалған үшеуден артық жоғарғы көрсеткіштерінің жиындық ұзындығын бағалауға негізделген туындатылған есту қарымы әдісінің көмегімен (BAER-тест) децеллюляризацияланған ксеноқұрсақ матриксін және кадаврдың консервіленген қатты ми қабығының мирингопластикасынан кейін есту қабілетіне салыстырмалы сипаттама берілді.

Қорытындысында сау құлақ пен жаңа биологиялық имплант қойылып операция жасалған құлақ арасында –  $53,2 \pm 13,55$  мм және  $40,6 \pm 9,77$  мм сәйкесінше ( $p > 0,05$ ) аудиограммадағы үшеуден артық орташа көрсеткіштерінің статистикалық маңызды өзгерістері анықталмады. децеллюляризацияланған ксеноқұрсақ матриксін қолдана отырып, жасалған мирингопластикадан кейінгі құлақтың шалғыштығы бастапқы көрсеткіштеріне жақын болып келеді.

*Кілт сөздер:* BAER тест, децеллюляризацияланған ксеноқұрсақ матриксі, биологиялық имплантат, мирингопластика, дабыл жарғағының перфорациясы