

A. Chesca<sup>1</sup>, A. B. Marchenko<sup>2</sup>, A. S. Akhaeva<sup>2</sup>

## STUDY OF PATIENTS WITH ACUTE RESPIRATORY PATHOLOGY WITH PACEMAKER IMPLANT

<sup>1</sup>Transilvania University of Braşov, Clinical Hospital of Pneumophysiology (Braşov, Romania),

<sup>2</sup>Karaganda state medical university (Republic of Kazakhstan)

Currently, cardiovascular and bronchopulmonary pathologies are the most urgent medical and social problems, in connection with maintaining a high level of mortality and morbidity. The present paper aims to bring attention to selected cases of patients who have carried out medical examination of acute respiratory symptomatology. Selected patients for the present study have comorbidities, acute and/or flare-up of chronic respiratory diseases and cardiovascular diseases requiring a pacemaker implant. Following routine investigations, including standard chest x-ray and anamnesis, had shown the combination of respiratory and cardiac symptomatology. This study also increased awareness of their condition, risks in patients with these diseases.

*Key words:* X-ray imaging, respiratory pathology, cardiovascular diseases, pacemaker

Respiratory pathology, by various symptoms worsen the quality of life and guide patients to medical specialized examinations [3, 12, 13]. In many situations, respiratory diseases affect patients of vulnerable ages, which contact with viruses, bacteria or fungi, that affect different segments of the upper airway or the lungs [8, 14].

Frequently, in all seasons of the year, but especially in the cold season, patients with cardiovascular disease are present in specialized departments with pneumophysiological profile [6]. We draw attention to elderly patients of both genders, who at the standard chest x-ray imaging investigation have present a pacemaker [1, 2]. Situations leading to the pacemaker implant are certain types of atrioventricular blocks, atrial fibrillation, carotid sinus hypersensitivity syndrome, sinus bradyarrhythmia, sinus node diseases [10, 15]. Artificial medical pacemaker is a device that uses electrical impulses, leading to myocardial function within normal limits, with a sustained, regular, rhythm of contraction capacity [7, 11].

In our practice such patients, are still relatively rare, in this regard, we pay them more attention. Radiological observation of the pacemaker, requires at least taking an anamnesis of the patient's cardiovascular disease associated with acute respiratory symptomatology [5, 9].

**Aim of research** was to improve diagnosis, medical awareness and adherence to therapy of patients with acute or chronic respiratory pathology with chronic cardiovascular diseases requiring a pacemaker implant.

### MATERIALS AND METHODS

In order to obtain this material, were selected patients, who have been presented for pneumological consultation and who have described associated cardiovascular disease in their anamnesis and being carriers of the pacemaker.

The patient's gender, age, home environment, diagnostic features of cardiovascular and respiratory diseases are considered. All patients from the present study were from urban residence area. The study involved 14 people, 78.57% (n=11) men and 21.43% (n=3) women. All examined were divided into two groups. First group was surveyed in the second quarter of 2016, 83.33% (n=5) men and 16.67% (n=1) female, the second group in the third quarter of the same year, 75% (n=6) men and 25% (n=2). In routine examinations such as standard chest X-ray, a pacemaker implant was observed at all patients.

### RESULTS AND DISCUSSION

The results of distribution of patients by gender showed on the figures 1, 2, 3. As shown in the diagram, there is a prevalence of male to female in general number of patients and in both groups. Differences in distribution between the two groups were not significant.

The predominance of men in the study reflects the fact that male sex is one of the main, unmodified risk factors for the development of cardiovascular diseases and their complications. It is also noted, that the male population has a higher percentage of smokers, which also increases cardiovascular risk and in particular the risk of developing persistent arrhythmias requiring the installation of a pacemaker [4].

The result of the sample distribution by age group is shown in Table 1. All patients were divided into 6 age groups with an interval of 9 years.

The most common age group, which is represented in the study, was a group of patients from 61 to 70 years, mainly due to the male population. In the second place were patients of the group <50 years old, with a uniform distribution across the sex.

Cardiovascular diseases from the selected

Table 1 – Sample distribution by age group

Age group, years	< 50	51-60	61-70	71-80	81-90	< 90
General population						
Cases, n (%)	2 (14.29)	1 (7.14)	8 (57.14)	1 (7.14)	1 (7.14)	1 (7.14)
Male population						
Cases, n (%)	1 (9.1)	1 (9.1)	7 (63.63)	1 (9.1)	0 (0)	1 (9.1)
Female population						
Cases, n (%)	1 (33.33)	0 (0)	1 (33.33)	0 (0)	1 (33.33)	0 (0)

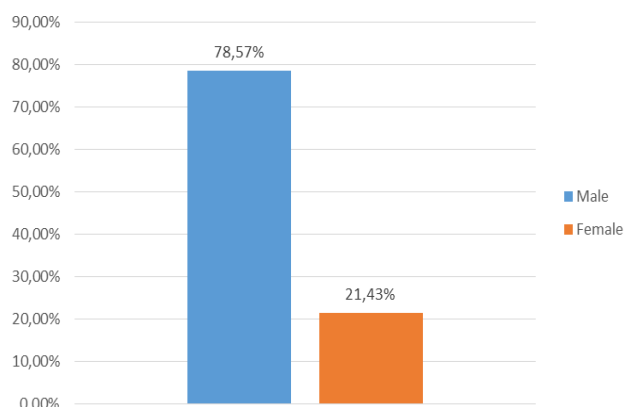


Figure 1 – Distribution of patients by gender, in both groups

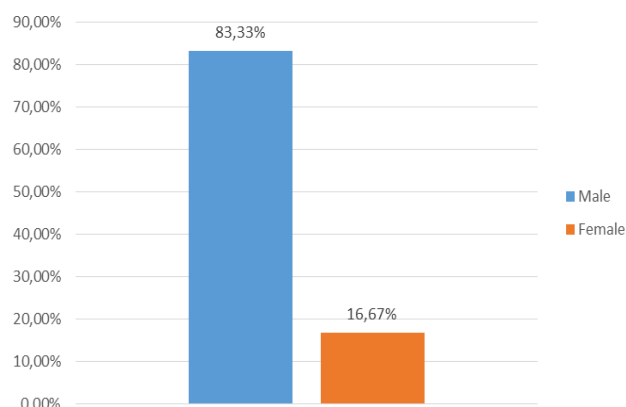


Figure 2 – Distribution of patients by gender, group 1

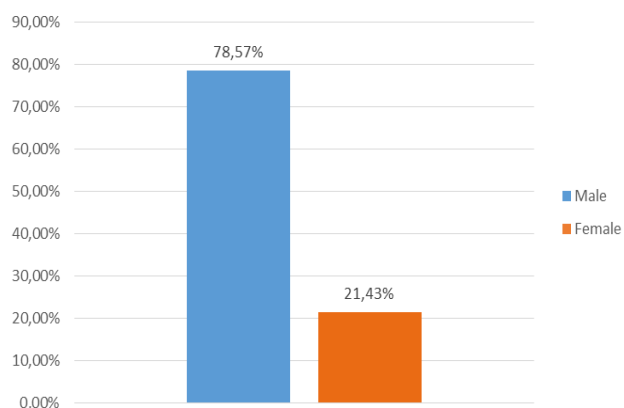


Figure 3 – Distribution of patients by gender, group 2

patients of the study were bundle branch block, sinus node disease, myocardial infarction, valvulopathy, heart failure; for example in one decompensated case, male patient 96 years old, was diagnosed pleural effusion.

The study continued, but in the manner of presenting suggestive radiological images (fig. 1, 2). Considering that the male gender is more affected than female gender, standard chest X-ray will be shown in two symptomatic patients with respiratory signs and symptoms, presented in specialized medical services, in the first quarter of

2018. The study could be continued from different perspectives.

### CONCLUSION

The combination of bronchopulmonary pathology with cardiovascular diseases, in particular, with heart rhythm disorders requiring the implantation of a pacemaker, significantly increases the risk of nonfatal (main disease prognosis worsening) and fatal complications such as a heart attack, stroke and pulmonary embolism. This, in turn, increases the importance of timely diagnosis and pathogenetic treatment of pulmonological pathology, consultation of pulmonologist. With each of the examined patients, was held a conversation on the need for timely consultation with related specialists, recommendations for further examination and treatment are detailed.

### REFERENCES

- Colquitt J. L. Implantable cardioverter defibrillators for the treatment of arrhythmias and cardiac resynchronisation therapy for the treatment of heart failure: systematic review and economic evaluation / J. L. Colquitt, D. Mendes, A. J. Clegg //Health Technol. Assess. – 2014. – V. 18 (56). – Pp. 1-560.
- Davies J G. Experience with implanted pacemakers: technical considerations //J. G. Davies, H. Siddons //Thorax. – 1965. – V. 20. – Pp.

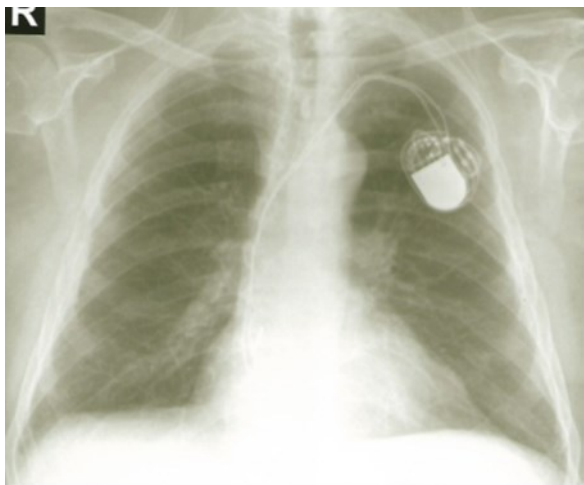


Figure 4 – Male, 84 years old

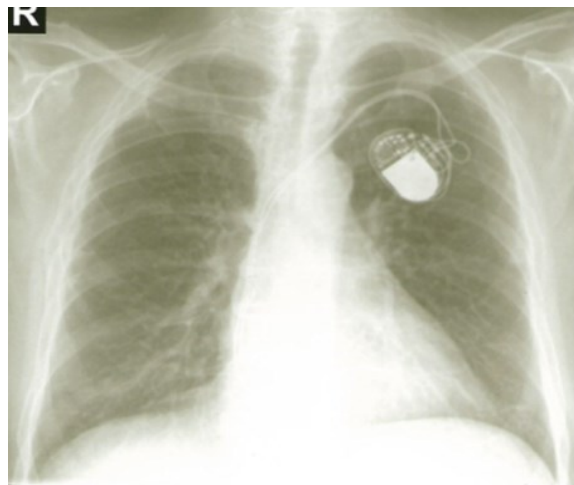


Figure 5 – Male, 74 years old

128-134.

3 Elahi M. M. Predictors of permanent pacemaker implantation during the early postoperative period after valve surgery /M. M. Elahi, D. Lee, R. R. Dhannapuneni //Tex. Heart. Inst. J. – 2006. – V. 33. – Pp. 455-457.

4 Feigin L. Global burden of stroke and risk factors in 188 countries, during 1990–2013: a systematic analysis for the Global Burden of Disease Study 2013 //The Lancet Neurology. – 2016. – V. 15 (9). – Pp. 913-924.

5 Fodstad H. Artificial respiration by phrenic nerve stimulation (diaphragm pacing) in patients with cervical cord and brain stem lesions / H. Fodstad, S. Blom, H. Linderholm //Scand. J. Rehabil. Med. – 1983. – V. 15(4). – Pp. 173-181.

6 Furman S. An intracardiac pacemaker for Stokes-Adams seizures /S. Furman, J. B. Schwedel //N. Engl. J. Med. – 1959. – V. 261. – Pp. 943-948.

7 Goodman C. C. Screening for medical problems in patients with upper extremity signs and symptoms //J. Hand Ther. – 2010. – V. 23 (2). – Pp. 105-125; quiz 126.

8 Greenspon A. J. Trends in permanent pacemaker implantation in the United States from 1993 to 2009: increasing complexity of patients and procedures /A. J. Greenspon, J. D. Patel, E. Lau //J. Am. Coll. Cardiol. – 2012. – V. 60. – Pp. 1540-1545.

9 Link M. S. Ventricular Tachyarrhythmias in Patients With Hypertrophic Cardiomyopathy

and Defibrillators: Triggers, Treatment, and Implications /M. S. Link, K. Bockstall, J. J. Weinstock //Cardiovasc. Electrophysiol. – 2017. – V. 28(5). – Pp. 531-537.

10 Liu X. L. Reasons and complications of pacemaker replacement operation: clinical analysis of 69 case-times /X. L. Liu, L. H. Ren, H. M. Ye //Zhonghua Yi Xue Za Zhi. – 2008. – V. 88. – Pp. 1989-1991.

11 Kane A. D. Infections secondary to pacemaker implantation: a synopsis of six cases /A. D. Kane, M. B. Ndiaye, S. Pessinaba //Cardiovasc. J. Afr. – 2012. – V. 23(10): e1-4.

12 Prabhakaran D. Cardiovascular, respiratory, and related disorders: key messages from Disease Control Priorities //The Lancet. – 2017. – V. 421. – Pp. 132-136.

13 Rizzuto D. Effect of chronic diseases and multimorbidity on survival and functioning in elderly adults //Journ. of the American Geriatrics Society. – 2017. – V. 65(5). – Pp. 1056-1060.

14 Verma A. Treatment of Patients With Atrial Fibrillation and Heart Failure With Reduced Ejection Fraction /A. Verma, J. M. Kalman, D. J. Callans //Circulation. – 2017. – V. 135(16). – Pp. 1547-1563.

15 Zhu J. Atrial Fibrillation Is an Independent Risk Factor for Hospital-Acquired Pneumonia / J. Zhu, X. Zhang, G. Shi //PLoS One. – 2015. – V. 10(7): e0131782.

Received 02.02.2018

А. Ческа<sup>1</sup>, А. Б. Марченко<sup>2</sup>, А. С. Ахаева<sup>2</sup>

ВЕДЕНИЕ ПАЦИЕНТОВ С ОСТРОЙ РЕСПИРАТОРНОЙ ПАТОЛОГИЕЙ И КАРДИОСТИМУЛЯТОРОМ

<sup>1</sup> Университет Трансильвании г. Брашов, Клинический госпиталь фтизиатрии (г. Брашов, Румыния),

<sup>2</sup> Карагандинский государственный медицинский университет (Караганда, Казахстан)

В настоящее время сердечно-сосудистая и бронхолегочная патология являются наиболее неотложными медицинскими и социальными проблемами в связи с высоким уровнем смертности и заболеваемости. Представ-

ленная работа направлена на привлечение внимания к отдельным случаям ведения пациентов, которым было проведено медицинское обследование острой респираторной симптоматики. Отобранные для исследования пациенты имели сопутствующие заболевания, острое и/или внезапно начавшееся хроническое респираторное заболевание и сердечно-сосудистые заболевания, требующие использования кардиостимулятора. После рутинных исследований, которые включали в себя стандартную рентгенографию и анамнез грудной клетки, была выявлена комбинация респираторной и сердечной симптоматики. Настоящее исследование также повысило осведомленность состояния, рисках у пациентов с этими заболеваниями.

*Ключевые слова:* рентгенография, респираторная патология, сердечно-сосудистые заболевания, кардиостимулятор

*А. Ческа<sup>1</sup>, А. Б. Марченко<sup>2</sup>, А. С. Ахаева<sup>2</sup>*

*ӨТКІР РЕСПИРАТОРЛЫҚ ПАТОЛОГИЯМЕН ЖӘНЕ КАРДИОСТИМУЛЯТОРМЕН ПАЦИЕНТТЕРДІ ЕМДЕУ*

*<sup>1</sup>Трансильвания университеті, Брашов қаласы, Клиникалық фтизиатрия госпиталі (Брашов қаласы, Румыния),*

*<sup>2</sup>Қарағанды мемлекеттік медицина университеті (Қарағанды, Қазақстан)*

Қазіргі уақытта жүрек-буын және тыныс алу-өкпе патологиясы ауыру менөлім-жітімнің жоғары деңгейіне байланысты барынша шұғыл медициналық және әлеуметтік мәселелер болып табылады. Ұсынылған жұмыс пациенттерді емдеудің жекелеген жағдайларына назар аударуға бағытталған, оларға өткір респираторлық симптоматикаға медициналық тексеру жүргізілген. Зерттеу үшін іріктелген пациенттердің қосалқы аурулары, өткір және/немесе кенет басталған созылмалы респираторлық ауруы мен кардиостимулятор пайдалануды талап ететін жүрек-буын аурулары болған. Стандарттық рентгенография мен кеуде клеткасының анамнезі сияқты көптеген зерттеулерден кейін, респираторлық және жүрек симптоматикасының комбинациясы анықталды. Осы зерттеу сол сияқты осы аурулармен пациенттердің жағдайы, қатерлері туралы хабардар болуларын арттырады.

*Кілт сөздер:* рентгенография, респираторлық патология, жүрек-буын аурулары, кардиостимулятор.